

## ORTHO-ENDO-PERIO: AN INTERPROFESSIONAL CASE REVIEW

Ashith MV<sup>1</sup>, Dhruv Ahuja<sup>2</sup>, Upasana Reddy<sup>3</sup>, Neetha Shetty<sup>4</sup>, Sakshi Sachdeva<sup>5</sup>, Yash Shekatkar<sup>6</sup>, Amoli Singh<sup>7</sup>

<sup>1</sup>Associate Professor, Department of Orthodontic and Dentofacial Orthopaedics, Manipal College of Dental Sciences Mangalore

Email: [ashith.mv@manipal.edu](mailto:ashith.mv@manipal.edu)

<sup>2</sup>Post-Graduate, Department of Orthodontic and Dentofacial Orthopaedics Manipal College of Dental Sciences Mangalore

Email- [dhruvahuja96@gmail.com](mailto:dhruvahuja96@gmail.com)

<sup>3</sup>Lecturer, Department of Conservative dentistry and Endodontics AB Shetty Memorial Institute of Dental Sciences, Mangalore, NITTE (Deemed to be University).

Email ID: [drupasana@nitte.edu.in](mailto:drupasana@nitte.edu.in)

<sup>4</sup>Professor and Head, Department of Periodontology, Manipal College of Dental Sciences Mangalore, Manipal Academy of Higher Education, Manipal, Karnataka.

Email ID: [neetha.rajesh@manipal.edu](mailto:neetha.rajesh@manipal.edu)

<sup>5</sup>Post-Graduate, Department of Orthodontics and Dentofacial Orthopedics, Manipal College of Dental Sciences Mangalore.

Email ID: [sakshisachdeva56@gmail.com](mailto:sakshisachdeva56@gmail.com)

<sup>6</sup>Reader, Department of Orthodontics, Yerla dental college and hospital, Khargar.

Email ID: [yash.shekatkar@gmail.com](mailto:yash.shekatkar@gmail.com)

<sup>7</sup>Senior lecturer, Department of Orthodontics and Dentofacial Orthopedics, Manipal College of Dental Sciences Mangalore.

Email ID: [singh.amoli@manipal.edu](mailto:singh.amoli@manipal.edu)

### ABSTRACT

The interdisciplinary approach is necessary to enhance the synergy between the three disciplines while improving the treatment outcomes and eliminating the existing barriers. Orthodontic treatment focuses on functional and aesthetic occlusion while endodontic therapy deals with the viability of dental pulp and root resorption, whereas, periodontal therapy aims to achieve healthy attachment of teeth with supporting structures. The orthodontic therapy has been used as an adjunct therapy to facilitate functional occlusion and tissue support, most of the periodontal and endodontic problems can be resolved by the correction of periapical pathology, traumatic injuries, pathological tooth migration, crowding, closure of midline diastema and many more. Need of the hour is to have a cross-disciplinary approach which helps the specialist in diagnosis and treatment planning, with accomplishment of planned treatment and solving any complications related to it. This mini review highlights the relevance of few cases and their systematic approach where orthodontic tooth movement is assisted by endodontic and periodontal therapy contributing to optimize treatment outcome of combined orthodontic-endodontic-periodontal problems.

**Key words:** pathological migration, orthodontic intrusion arch mechanics, multidisciplinary approach

### INTRODUCTION

The interaction, co-ordination and co-operation between different dental specialties plays a key

role in establishing diagnosis and treatment planning. Most of the adult patients seek orthodontic therapy for functional and aesthetic goals, presents a challenge to orthodontists

because of existing systemic medical condition and dental conditions including attrition, over hanging and poorly shaped restorations, and also oral hygiene status associated with periodontal diseases.

Oral hygiene of a patient plays a vital role during orthodontic therapy as it is directly related to the timing and quality of the treatment. Orthodontic appliances are associated with an increase in plaque retention which further brings about the risk associated with gingival inflammation and therefore leading to periodontal problems.

The orthodontist should identify oral hygiene status along with inflammatory periodontal diseases as periodontal pathology is a multifactorial process, and the successful outcome of short and long term orthodontic treatment is dependent on the patient's oral hygiene status throughout the active orthodontic therapy.<sup>(1)</sup>

Periodontal pathology is commonly associated with adults and there is risk of gingival inflammation with loss of attachment and bone loss. Loss of attachment, shifts the centre of

resistance apically and increases the distance from the force application point to the centre of resistance, which increases the unwanted tipping moment than that of the healthy tooth and also the adult bone is sensitive to orthodontic force. Hence, lighter orthodontic force should be used with periodontal diseases.<sup>(2)</sup>

### INTERDISCIPLINARY APPROACH FOR PREVENTION AND TREATMENT OF A PATHOLOGY

Orthodontic therapy improves the stomatognathic function with proper occlusal stability and alignment of the teeth. This helps in better speech, mastication and facial aesthetics, while endodontic therapy deals with the dental pulp viability and root resorption, whereas periodontal therapy establishes healthy attachment of teeth with supporting structures and contributes to oral and overall health, with improvement in quality of life.<sup>(3)</sup>

Based on previous studies the sequence of orthodontic-endodontic-periodontal planning is structured into the following stages<sup>(4)</sup>

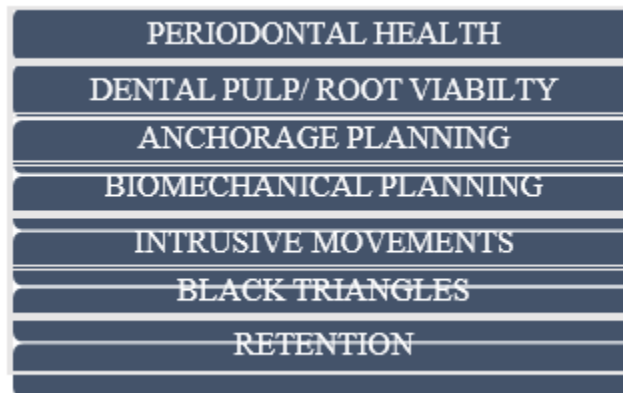


Table-1: SEQUENCE OF ORTHO-ENDO-PERIO TREATMENT

### TISSUE ARCHITECTONICS WITH MULTIDISCIPLINARY APPROACH

Case history, appropriate medical history, clinical evaluation with periodontal screening are essential for primary diagnosis to establish

treatment plan. Periodontal therapy paves the way for orthodontic treatment to secure healthy periodontal attachment with reduced inflammatory signs and pocket depths along with associated symptoms. Most commonly in adult patient with periodontal diseases may experience

pathological tooth migration with tipping and extrusion of one or more anterior teeth leading to spaces between anterior teeth.

<sup>(5)</sup> Care should be taken while placing orthodontic appliances at some distance from subgingival environment, so as to prevent plaque development and inflammation.<sup>(6)</sup>

The case reports describe the advantages of the holistic approach of orthodontic, periodontal and endodontic multidisciplinary therapies in case of periodontitis that causes pathologic migration with extrusion of a maxillary and mandibular anterior teeth.

### Case Report 1

A patient aged 28 years reported to the department of Orthodontics and Dentofacial Orthopedics at Manipal College of Dental Sciences, Mangalore, Karnataka, India with chief complaint of spacing and discoloured upper front teeth. Patient had history of fall 15 years back following which he developed discoloured maxillary central incisors. Thorough clinical examination revealed proclination of upper and lower anterior teeth, spacing and grade II mobility with respect maxillary and mandibular anterior teeth. Soft tissue examination revealed gingival inflammation with deep periodontal pockets. Radiographic evaluation revealed angular bony defect wrt 21 & 23, periapical radiolucency wrt 11 & 21 and generalised horizontal bone loss.

The 28-year-old patient has been diagnosed with

Angles class II subdivision with chronic generalised periodontitis, pathological migration and non-vital 11 & 21.

Treatment plan was decided after multidisciplinary opinions which includes:

1. Periodontal therapy- to maintain good oral hygiene
2. Endodontic therapy- to treat periapical pathology wrt 11 & 21
3. Periodontal flap surgery to eliminate existing pockets and achieve good oral hygiene
4. Orthodontic therapy- achieve facial aesthetics and to obtain stable occlusion with optimal overjet and overbite

After initial prophylactic therapy and endodontic treatment including healing period of 6 months, which after re-evaluation showed reduction in gingival inflammation, bleeding on probing and pocket depth following which Orthodontic treatment was started with 0.14 NiTi using segmental arch technique followed by 0.16 Australian and 16\*22ss.

Initially during levelling and alignment treatment was stopped in lower arch because of the increasing mobility in lower anteriors and fibre reinforced splint was given to reduce the mobility, following which the orthodontic treatment was started again with Intrusion arch given with 17\*25 TMA wire for intrusion of anteriors and to open the bite, while space closure was done using closing loop mechanics using T-loop.

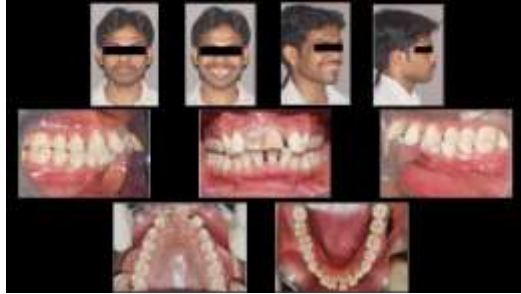

Fig 1: Pre-treatment extraoral and intraloral

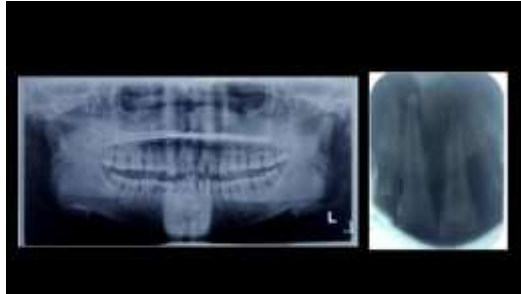


Fig 2: Pre-treatment radiographs showing bone loss and periapical pathology

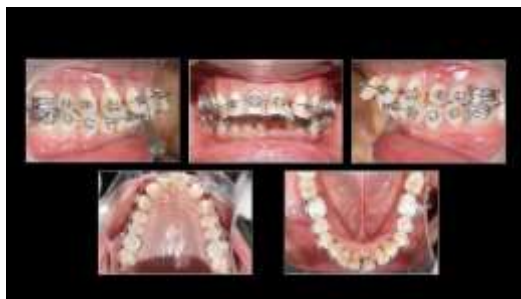

Fig 3: segmental arch technique for lighter orthodontic force application

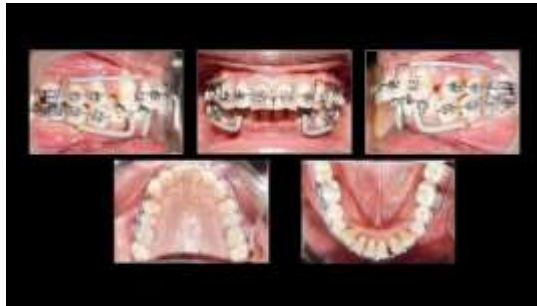

Fig 4: intrusion arch with 17\*25 TMA wire for extruded maxillary and mandibular anterior teeth

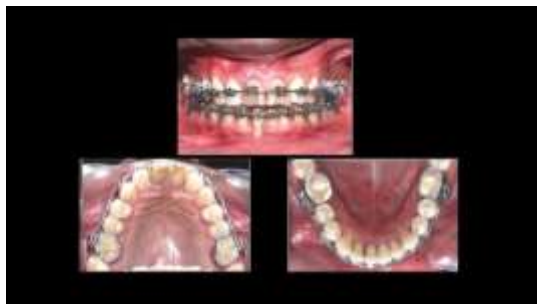

Fig 5: intruded maxillary and mandibular anterior teeth

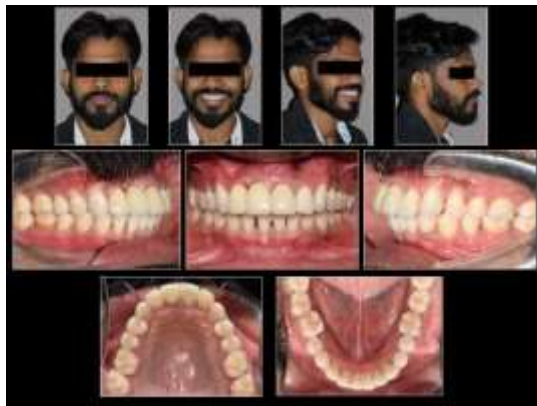

Fig 6: Post treatment intraoral and Extraoral

### Case Report 2

A 24yr old female patient reported to our department with chief complaint of spacing in upper front teeth. On clinical evaluation revealed mutilated molar relation, extrusion of maxillary anterior teeth with spacing and grade 2 mobility was observed whereas, soft tissue examination revealed gingival hyperplasia with periodontal pockets and radiographic evaluation showed generalised horizontal bone loss.

A 24-year-old female patient has been diagnosed as Angles class I with chronic generalized periodontitis having trauma from occlusion with pathological migration wrt 13,12,11,21,22 &23

Orthodontic therapy with segmental arch mechanics and intrusion arch was initiated after completion of periodontal phase 1 therapy, which included thorough subgingival scaling and root planning which improved the tissue attachment and surrounding structures.

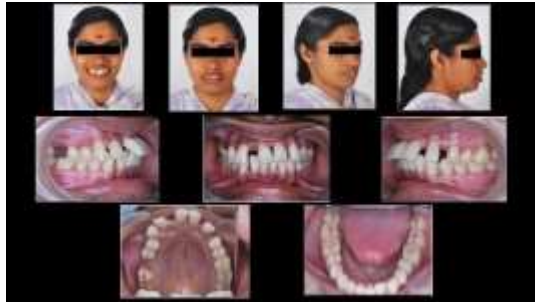

Fig 6: Pre-treatment extraoral and intraloral photographs

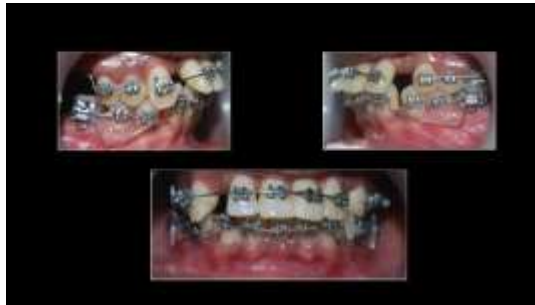

Fig 7: segmental arch technique and intrusion utility arch

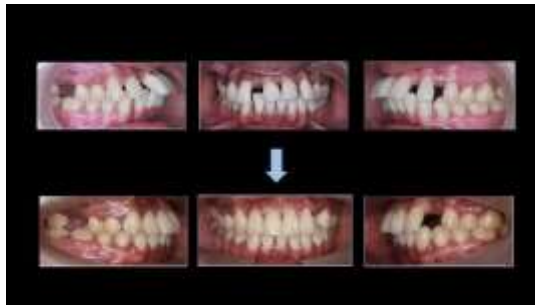

Fig 8: pre and post treatment comparison of intraoral photographs




Fig 9: pre and post treatment comparison of extraoral photographs

**DISCUSSION**

The combined multidisciplinary approach can significantly improve the periodontal health, stomatognathic function, root resorption status, stable occlusion and dentofacial aesthetics. Periodontal pathology may lead to pathological migration and associated bony defects with tooth mobility. In such conditions, adjunctive orthodontic therapy can be the most dependable therapeutic approach to align migrated or

extruded teeth after completion of periodontal therapy.

Roberts and Chase <sup>(7)</sup> concluded that orthodontic tooth movement enhances the intercellular pursuit of the periodontal ligament. On the other hand, Melsen et al. <sup>(8)</sup> showed that intrusive movement of tooth leads to new tissue attachment of the supporting structures which is the most effective and conservative method to realign pathologically migrated teeth after achievement

of good oral hygiene.<sup>(9)</sup>

Orthodontic therapy with lighter force mechanics aids in easy movement of periodontally compromised teeth; whereas, heavy orthodontic forces affects the periodontal health and can cause bone and root resorption.<sup>(10)</sup> Elimination of plaque and gingival inflammation will eventually lead to better orthodontic treatment results with periodontitis patients.<sup>(11)</sup>

Geiger et al. has reviewed few studies and concluded that tooth malalignment is the main cause of periodontal pathologies.<sup>(12)</sup> Behlfelt et al. concluded periodic oral health check-ups during orthodontic therapy is essential to minimise the effect of gingival inflammation and periodontal diseases<sup>(13)</sup>

In the present case reports the patients were treated with segmental arch technique using lighter forces to intrude the pathologically migrated teeth while improving facial profile and occlusal stability. Periodontal health was significantly improved in both the patients after maintenance phase therapy wherein the pocket depth reduced from 7-8mm to 3-4mm with no bleeding on probing showing reduction in mobility from grade 2 to grade 1. Improvement in bony contour and adjacent soft tissue structures was observed with the completion of orthodontic treatment.

Gyawali et al. in 2017, observed that orthodontic treatment is feasible with aggressive periodontitis patients, provided the disease is controlled by periodontal therapy.<sup>(14)</sup> Regenerative periodontal surgery is suggested, when pocket depth and loss of attachment has not been fully accomplished after the maintenance phase. Orthodontic therapy can be looked thoughtfully for a long time after thorough periodontal healing and the placement of orthodontic appliances should be done carefully in order to prevent plaque accumulation and periodontal inflammation.<sup>(15)</sup>

## CONCLUSION

With the improvement in quality of life most of the adult patients seek periodontal therapy for healthy attachment of supporting structures

around the teeth along with orthodontic therapy for functional and aesthetic stability. Inter disciplinary approach with good oral hygiene care and orthodontic modification transform patients with unpleasing dentition due pathological migration or any periodontal disease into individuals with pleasing dentition and delightful smile. This multidisciplinary approach seems to be an effective method, ensuing in notable periodontal and aesthetic improvements.

## REFERENCES

- [1] Shekhar S, Lakshmi B, Shekhar C, Shivamallu A: Periodontal considerations during orthodontic treatment. *Indian Journal of Oral Health and Research*, January 2017; 3(1):1
- [2] Bagga DK. Adult orthodontics versus adolescent orthodontics: An overview. *J Oral Health Comm Dent* 2010;4:42-7
- [3] Alfuriji S, Alhazmi N, Alhamlan N, Al-Ehaideb A, Alruwaithi M, Alkathheeri N, Geevarghese A, "The Effect of Orthodontic Therapy on Periodontal Health: A Review of the Literature", *International Journal of Dentistry*, vol. 2014
- [4] Seixas, MR. A pirâmide das necessidades estéticas do sorriso. *Rev Clín Ortod Dental Press*. 2019 Ago-Sept;18(4):34-44.
- [5] Feu D, Orthodontic treatment of periodontal patients: challenges and solutions, from planning to retention, *Dental Press J. Orthod*. 25 (06) • Nov-Dec 2020
- [6] Doulkeridou C, Vouros I, Petridis A, Athanasia-Eirini Z, Theodoridis C. Interdisciplinary Approach in Periodontology - A Mini-Review and A Report of Two Complex Cases. *Dental Research and Oral Health* 3 (2020): 107-120
- [7] Roberts WE, Chase DC. Kinetics of cell proliferation and migration associated with orthodontically-induced osteogenesis. *J Dent Res* 1981;60:174-81.
- [8] Melsen B, Agerbaek N, Eriksen J, Terp S. New attachment through periodontal treatment and orthodontic intrusion. *Am J Orthod Dentofacial Orthop* 1988;94:104-16.
- [9] Deepa D, Mehta D S, Puri VK, Shetty S. Combined periodontic-orthodontic-

- endodontic interdisciplinary approach in the treatment of periodontally compromised tooth. *J Indian Soc Periodontol* 2010;14:139-43
- [10] Dannan A, Darwish MA, Sawan MN. How do periodontal tissues react during orthodontic alignment & leveling phase. *Virtual J Orthod* 2008;8:1-7
- [11] Rajavel AK, Varma AJ, Ilangovan K, James L; Orthoperio Management for a Patient with Aggressive Periodontitis, *Journal of Scientific Dentistry*, Volume 9 Issue2 (July-December 2019)
- [12] Re S, Corrente G, Abundo R, Cardaropoli D. Orthodontic treatment in periodontally compromised patients: 12-year report. *Int J Periodontics Restorative Dent* 2000;20(1):31-39.
- [13] Behlfelt K, Ericsson L, Jacobson L, Linder-Aronson S. The occurrence of plaque and gingivitis and its relationship to tooth alignment within the dental arches. *J Clin Periodontol* 1981;8(4):329-337
- [14] Gyawali R, Bhattarai B. Orthodontic management in aggressive periodontitis. *Int scholarly Res* 2017;2017:8098154
- [15] Nadimpalli H, Deepa K, David K. Perio-Ortho Interactions-A Review *J. Pharm. Sci. & Res.* Vol. 10(5), 2018, 1053-1056